



PATIENT
Whitey Bulger Colella

PRESENTING CLINICAL SIGNS

History: Elevated ProBNP (873). No murmur. History of kidney disease.

SPECIES
Feline

ECHOCARDIOGRAM FINDINGS

2D, m-mode, color flow and Doppler imaging is available.

BREED
Devon Rex

Left ventricle: The LV diameter is normal with adequate myocardial function. Mildly increased sphericity. The LV wall thicknesses are normal with regions of thinning along the septum. There is a diffusely hyperechoic endocardium consistent with mild fibrosis. The papillary muscles are mildly remodeled and hyperechoic.

SEX
Maled Neutered

Left atrium: The left atrium is mildly dilated and bulbous. No obvious spontaneous contrast or thrombi seen.

Mitral valve: The mitral valve is normal in structure and mobility with no mitral regurgitation. No obvious systolic anterior motion is seen.

AGE
10 years

Aortic valve/aorta: The aortic valve is normal in morphology and mobility. Normal aortic outflow velocity; laminar flow. No aortic insufficiency.

Right ventricle: Normal right ventricular diameter and morphology indicating no overt evidence of pulmonary arterial hypertension.

WEIGHT
10lbs

Right atrium: The right atrium is normal in dimension.

Tricuspid valve: The tricuspid valve appears normal with trace tricuspid regurgitation.

Pulmonic valve/pulmonary artery: The pulmonic valve is normal in morphology and mobility. No pulmonic insufficiency. Normal RVOT velocity; laminar flow.

Pericardium/other: No pericardial or pleural effusion noted. No obvious cardiac masses.

Heart rhythm: ECG reveals a sinus rhythm with an average HR of 200bpm.

INTERPRETED BY

Maggie Machen
Lamy, DVM
DACVIM (Cardiology)

2-Dimensional Measurements

| | |
|--------------------|------|
| Ao diam (cm) | 0.8 |
| LA diam (cm) | 1.36 |
| LA:Ao (Swe) | 1.5 |
| IVS thickness (cm) | 0.31 |
| LVID diastole (cm) | 1.4 |
| PW thickness (cm) | 0.40 |
| LVID systole (cm) | 0.49 |
| FS (%) | 65 |

Doppler Measurements

| | |
|----------------|------|
| PV Vmax (m/s) | 0.77 |
| AoV Vmax (m/s) | 1.1 |
| MR Vmax (m/s) | NA |
| TR Vmax (m/s) | NA |
| TR PG (mmHg) | NA |

IMAGING PERFORMED BY

Pamela Harrigan,
RDCS

HOSPITAL NAME

Wignall Animal
Hospital

INTERPRETATION OF THE FINDINGS

Mild abnormalities are identified. First is the LV is mildly spherical with regions of wall thinning. Additionally the LA is mildly dilated, which may suggest early filling pressure elevation. No hypertrophy or other pathology is appreciated. These findings may reflect early restrictive disease (RCM), particularly in light of an elevated BNP value. Serial echocardiography will be necessary to determine progression.

REFERRING VET

Dr. Colella

RECOMMENDATIONS

- Given these findings, no medications are indicated.
- Baseline BP is recommended.
- The risk for general anesthesia is low, however heart rate stimulating drugs such as atropine, glycopyrrolate, etc. should be avoided unless medically necessary. With this degree of LV remodeling there may be an elevated risk for fluid overload in this patient and judicious IV fluid use is recommended.

INVOICE
28741

DATE
2/1/23



PATIENT
 Whitey Bulger Colella

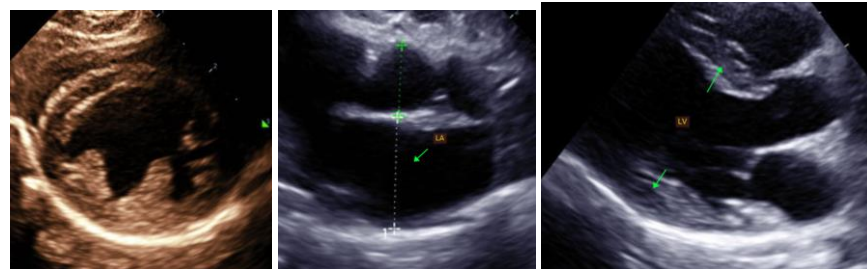
- Monitor for any clinical evidence of cardiac compromise, including respiratory changes and/or signs of a blood clot event (paralysis, neurologic changes, etc).

SPECIES
 Feline

- PLAN**
- Recommend recheck echocardiogram in 6-12 months to reassess murmur origin and screen for progressive LA dilation.

BREED
 Devon Rex

IMAGES



SEX
 Maled Neutered

AGE
 10 years

The information and recommendations provided are based on the images presented by the referring veterinarian. No evaluation can be communicated regarding pathology that was not visible in the image/video clips provided.

WEIGHT
 10lbs

Thank you for this referral. This report was generated using transcription software, and minor dictation errors may be present. If the clinical or image interpretation does not parallel your findings or if I can be of any further assistance, please contact me.

INTERPRETED BY
 Maggie Machen
 Lamy, DVM
 DACVIM (Cardiology)

Maggie Machen Lamy, DVM
Diplomate of the American College of Veterinary Internal Medicine (Cardiology)
 info@sonopath.com

IMAGING PERFORMED BY
 Pamela Harrigan,
 RDMS

Echocardiogram performed by: Pamela Harrigan, RDMS
 Pet Animal Ultrasound Service (4paus.com)

HOSPITAL NAME
 Wignall Animal
 Hospital

REFERRING VET
 Dr. Colella

INVOICE
 28741

DATE
 2/1/23